

Evaluation of Diagnostic Efficacy of Pipelle Endometrial Sampling in Abnormal Uterine Bleeding

ABILASH SASIDHARANNAIR CHANDRAKUMARI¹, HEMALATHA A LINGAPPA², SHREELAKSHMI DEVI SINGARAVELU³

ABSTRACT

Introduction: Abnormal Uterine Bleeding (AUB) is a major clinical problem among women in peri and postmenopausal age groups which needs complete scrutiny. Various methods are in vogue for the assessment of endometrium. Histopathological interpretation of endometrial tissue is the gold standard investigation. Studies have raised concern about diagnostic accuracy and adequacy of pipelle endometrial sample.

Aim: To compare the efficacy of pipelle endometrial sampling method with conventional Dilatation (D) and Curettage (C) in diagnosis of AUB.

Materials and Methods: This comparative cross-sectional study was carried out at DM Wayanad Institute of Medical Science, Kerala, India (January 2016 to June 2017). Endometrial samples collected from 210 patients with AUB initially by pipelle method followed by D and C formed the material for this study. Slides were prepared after routine histopathological processing and sectioning. Staining was done using Haematoxylin and Eosin (H&E) stains and the slides were subjected to thorough and independent microscopic examination for comparative analysis. Data analysis was performed using IBM SPSS Software version 21.0.

Results: Histopathological examination of endometrial samplings by pipelle method revealed endometrial carcinoma in seven cases, atypical endometrial hyperplasia in seven cases, endometrial hyperplasia in 85 cases and disordered proliferative endometrium in 30 cases. These were correlated with histopathological findings of conventional D and C sampling method which showed pipelle sampling method had sensitivity and specificity in endometrial carcinoma (80% and 100% respectively), atypical endometrial hyperplasia (100% and 99.5% respectively), endometrial hyperplasia (100% and 93.98% respectively) and disordered proliferative endometrium (81.1% and 100% respectively). There was significant positive correlation ($p < 0.01$) between the two techniques. Endometrial sampling by pipelle method had a high sensitivity and negative predictive value in diagnosing abnormal endometrium.

Conclusion: Endometrial sampling by pipelle method is a safer and simpler alternative for diagnosis of endometrial lesions in patients with AUB. It has a fair degree of diagnostic accuracy almost comparable to that of curettage material. The diagnostic accuracy is high if interpreted by an experienced pathologist.

Keywords: Atypical endometrial hyperplasia, Carcinoma, Dilatation and curettage, Endometrial hyperplasia

INTRODUCTION

The AUB is a major clinical problem among women in the reproductive, peri and postmenopausal age groups. The AUB in women aged 40 and older, especially in peri and post-menopausal age group requires exclusive assessment, to exclude atypical endometrial hyperplasia and carcinoma [1]. Histopathological examination of endometrial tissue remains the mainstay in the evaluation of AUB. In the recent scenario, endometrial sampling is being obtained by various invasive and non invasive techniques such as pipelle technique, D and C and hysteroscopy guided curettage. The advent of non invasive office procedures like pipelle endometrial sampling has posed a challenge to the whole range of conventional invasive techniques. It is now widely accepted by the clinicians and patients, since they are safe and economical. The conventional modalities like D and C and hysteroscopy guided curettage may require hospitalisation and anaesthesia; hence, they are too heavy on patient's pocket [2]. Pipelle endometrial sampling has been gaining popularity as the most convenient method of sampling endometrial lining in the recent times. It can sample about 5-15% of the total endometrial surface area [3]. It is especially useful in global lesions involving in large surface area of the endometrium than in focal lesions [4].

The D and C is the most conventional method of endometrial sampling which is in vogue since many decades. Though, it offers a high degree of sensitivity in diagnosis of endometrial lesions, the associated surgical risks, postoperative pain, higher costs due to

hospitalisation and anaesthesia have necessitated the search for a suitable substitute which is simpler, cheaper, non invasive, free of complications and offers good diagnostic accuracy [5]. Previous studies have raised concern in regard to adequacy of endometrial sample procured and accuracy rate in diagnosing endometrial hyperplasia by pipelle method [6,7]. Hence, the present study was proposed to evaluate the efficacy of pipelle sampling in diagnosing endometrial pathologies in comparison with gold standard D and C method.

MATERIALS AND METHODS

This comparative cross-sectional study was carried out in the Department of Pathology at DM Wayanad Institute of Medical Science, Wayanad, Kerala, India, for over a period of 18 months from January 2016 to June 2017. Institutional Ethical Committee approval was obtained and a total of 210 patients with the indication of endometrial sampling were evaluated. Detailed clinical history inclusive of laboratory investigation reports and radiological findings were recorded from the institutional records.

The AUB patients with no obvious cervical lesions and without any haematological disorders were included in the study. Patients with lower genital tract/pelvic infections, known cases of cervical stenosis, cervicitis, premalignant and malignant cervical lesions or pregnancy were excluded from the study.

After getting informed consent pipelle endometrial sampling was performed followed by dilatation and uterine curettage. Through,

undilated cervix the pipelle device was introduced into uterine cavity without anaesthesia. The piston is fully withdrawn to create suction and the device is rotated to get a sample which was collected in formalin bottle. Endometrial sample was sent for histopathology.

The endometrial samples obtained by two different methods were introduced in 10% formalin, processed by routine histopathological techniques and paraffin blocks were prepared. From each block about 3-4 μ m sections were cut, mounted, dewaxed and stained with H&E. The slides were submitted to detailed microscopic examination and were evaluated independently. The microscopic findings and histopathological diagnosis in each case by pipelle aspiration techniques and curettage were separately recorded and comparative analysis undertaken.

STATISTICAL ANALYSIS

Data analysis was performed by using IBM Statistical Package for the Social Sciences (SPSS) software version 21.0. Sensitivity, specificity, Positive Predictive Value (PPV), Negative Predictive Value (NPV) and diagnostic accuracy were calculated.

RESULTS

All 210 endometrial samples were evaluated in the study. The mean age of the studied population was 44.6 years (Standard deviation 7.04; age ranged between 31 and 66 years). Majority of the patients (131) were perimenopausal. Menorrhagia was the most common presenting complaint seen in 116 cases (55.24%), followed by metrorrhagia in 48 (22.86%) cases, Polymenorrhea in 28 (13.33%) cases and postmenopausal bleeding in 18 (8.57%) cases.

Pipelle sample was found inadequate for evaluation in 10 cases while all the 210 D and C samples were adequate for histopathological examination. A sample was labelled as inadequate by the histopathologist when no endometrial tissue were present [Table/Fig-1]. Comparison of histopathological findings between two endometrial sampling methods is shown in [Table/Fig-2].

Endometrial sampling method	Adequate (n=210)	Inadequate (n=210)
Pipelle	200 (95.24%)	10 (4.76%)
D and C	210 (100%)	-

[Table/Fig-1]: Comparison of adequacy of endometrial sampling by different methods.

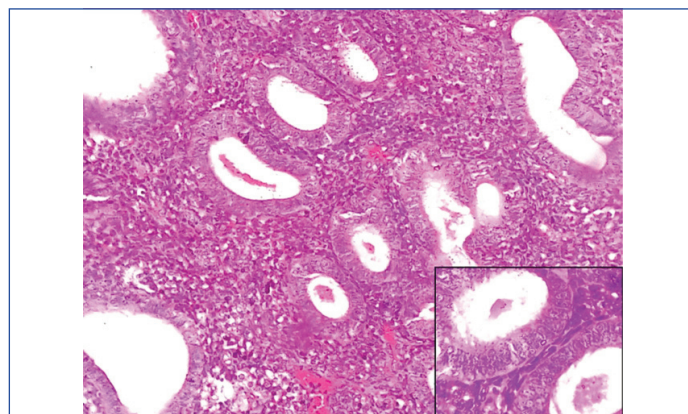
D and C: Dilatation and Curettage

Histopathologic category	Pipelle method	Dilatation and curettage
Proliferative phase	34	37
Secretory phase	25	25
Disordered proliferative endometrium	30	37
Hormone induced changes	05	08
Atrophic endometrium	06	10
Endometrial hyperplasia	85	77
Atypical endometrial hyperplasia	07	06
Endometrial adenocarcinoma	07	09
Choriocarcinoma	01	01
Not adequate	10	-
Total	210	210

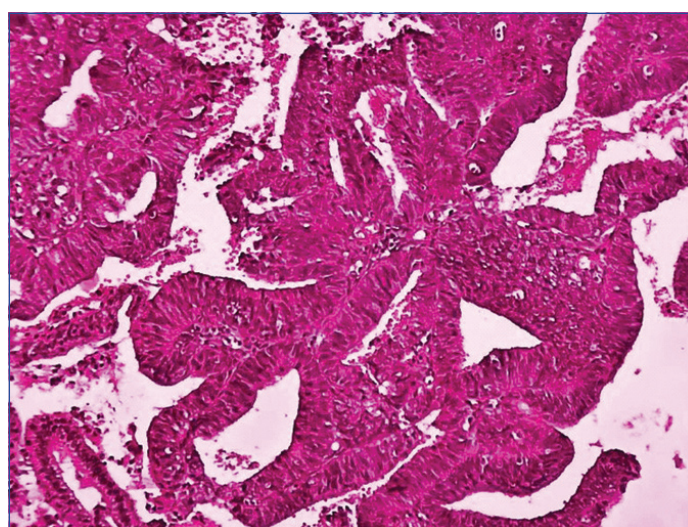
[Table/Fig-2]: Histopathological findings of endometrial samples obtained by pipelle and dilatation and curettage.

In the present study, of the 85 cases reported as endometrial hyperplasia by pipelle method, 77 cases showed positive correlation with D and C [Table/Fig-3], the remaining cases turned out to be disordered proliferative (5), secretory endometrium (1), hormone related changes (1) and atrophic endometrium (1). These cases were considered as false positives for endometrial hyperplasia. Among seven cases diagnosed as atypical endometrial hyperplasia by pipelle method, D and C concurred with six cases and the case

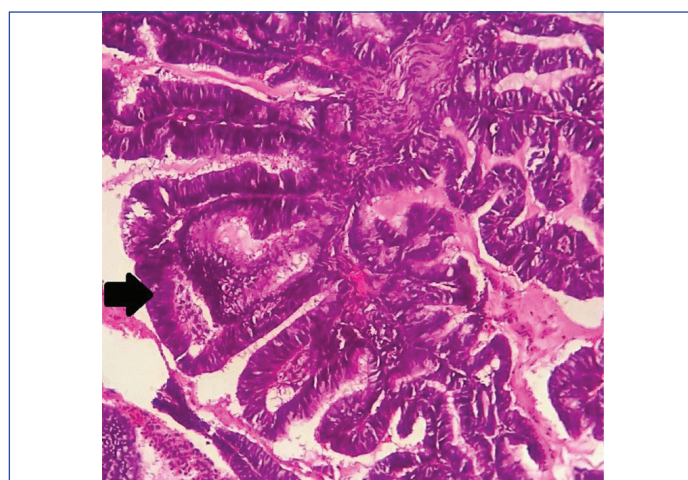
diagnosed as atypical hyperplasia with suspicion of invasion was proved to be endometrial carcinoma by D and C [Table/Fig-4]. All the seven cases diagnosed as endometrial carcinoma by pipelle method were found to be in agreement with D and C [Table/Fig-5].



[Table/Fig-3]: Photomicrograph of pipelle sample showing endometrial hyperplasia without atypia (10X and 40X [inset], H&E staining).



[Table/Fig-4]: Photomicrograph of pipelle sample showing endometrial hyperplasia with atypia (H&E staining, 10X).



[Table/Fig-5]: Photomicrograph of pipelle sample showing endometrial carcinoma, villoglandular type (black arrow) (H&E staining, 10X).

Histopathological examination of D and C samples detected 37 cases of disordered proliferative endometrium while pipelle method detected 30 cases, a diagnosis of endometrial hyperplasia was made on five cases and two cases of pipelle were found inadequate for evaluation. Of the eight cases diagnosed as hormone related changes by D and C, pipelle method detected five cases, one case was diagnosed as endometrial hyperplasia and two cases were opined to be inadequate for a definite opinion by pipelle method. The diagnosis of atrophic endometrium was made on 10 cases by

Variables	Proliferative endometrium	Secretory endometrium	Disordered proliferative endometrium	Atrophic endometrium	Hormone related changes	Endometrial hyperplasia	Atypical endometrial hyperplasia	Endometrial carcinoma
Sensitivity	91.9	96	81.1	60	62.5	100	100	80
Specificity	100	99.46	100	100	100	93.98	99.5	100
PPV	100	96	100	100	100	90.50	85.7	100
NPV	98.3	99.46	96.1	98.04	98.54	100	100	99
Accuracy	98.57	99.05	96.67	98.01	98.57	96.2	98.57	99.05

[Table/Fig-6]: Lesion wise statistical variables in pipelle endometrial samples.

PPV: Positive predictive value; NPV: Negative predictive value

D and C sampling, out of which, pipelle detected six cases, three cases were found inadequate for reporting and one case was diagnosed as endometrial hyperplasia by pipelle.

In the present study, pipelle sampling had 100% sensitivity and 100% NPV in detecting endometrial hyperplasia, atypical endometrial hyperplasia and choriocarcinoma. It showed 100% specificity and 100% PPV in diagnosing endometrial carcinoma, disordered proliferative and proliferative endometrium. The sensitivity rate in diagnosing atrophic endometrium and hormone related changes were found to be 60% and 62.5% respectively. The overall diagnostic accuracy rate of pipelle sampling was 98.09% [Table/Fig-6].

DISCUSSION

Endometrial sampling is an indispensable and an outstanding tool in the assessment of underlying pathology in patients with AUB [8,9]. Pipelle endometrial sampling yields good accuracy rate when reported by an experienced pathologist. Pipelle procedure requires less than a minute to perform and produces hardly any post procedure bleeding or patient discomfort.

The main purpose of endometrial sampling is early detection of endometrial hyperplasia and carcinoma. Endometrial sampling by pipelle method is an outpatient procedure and its advantages include low cost, minimal risk for the patient, non requirement for anaesthesia and least discomfort or pain [10]. However, the procedure yields sufficient sample adequate for the interpretation by a pathologist. The probability of processing an adequate sample is even higher when the endometrial thickness is assessed by prior ultrasound imaging as more than 5 mm [11,12].

Pipelle endometrial sampling scores over D and C in its simplicity as it can be performed without anaesthesia or analgesia during routine pelvic examination. In the present study, pipelle sampling was done followed by D and C sampling in order to maintain the synchrony in sampling which is mandatory for a comparative analysis.

In the present study, despite the fact that pipelle method had low sensitivity in detecting atrophic endometrium and disordered proliferative endometrium, it showed high NPV (98.04% and 96.1% respectively) and high accuracy rate (98.01% and 96.67% respectively). These findings are in accordance with the study done by Aron T et al., which also showed that pipelle endometrial sampling method had an accuracy rate of 95.5% and NPV of 98.8% in diagnosing atrophic endometrium [13].

Chaudry A and Javaid M, and Behnamfar F et al., had concluded in their studies that pipelle technique is an accurate and a widely accepted endometrial sampling technique in comparison with sampling by D and C [14,15]. The obtained observation are in concurrence with these studies as the sensitivity, specificity and accuracy rates for pipelle sampling were almost on par with the D and C sampling in the assessment of endometrial lesions.

Clark TJ et al., recommended in their study that, due to the moderate accuracy rates observed in diagnosing endometrial hyperplasia on pipelle sampling, additional and supportive assessment should be supplemented along with pipelle sampling [16].

Dijkhuizen FP et al., and Rachamalla L et al., observed in their meta analysis that pipelle endometrial sampling is an effective

diagnostic tool in diagnosing atypical hyperplasia and carcinoma [17,18]. Studies done by Chandrashekar N et al., and Patil P et al., showed that pipelle method had a specificity rate (99% and 98% respectively) and accuracy rate (98% and 99%) respectively in diagnosing endometrial carcinomas, present findings showed good congruence with these studies [6,19].

LIMITATION

There are few limitations concerning this study. This was single hospital based study with small sample size, so results of this study cannot be generalised. Taking this study as reference point, future multicentric research with larger sample size involving higher number of postmenopausal cases can be planned.

CONCLUSION

Pipelle endometrial sampling is a non invasive outpatient procedure with diagnostic accuracy rate paralleling that of D and C sampling. Clinicians and patients find it more convenient and acceptable technique. Coupled with its additional benefits of high sampling adequacy, it is not far behind in becoming an unequivocal and indispensable tool in the diagnosis of endometrial lesions.

ACKNOWLEDGEMENTS

The authors acknowledge Dr. Geetha Vasu, Professor and Head, Department of Pathology and Dr. PG Konapur, Professor, Department of Pathology, for their continuous support and encouragement.

REFERENCES

- [1] Goldstein SR. Modern evaluation of the endometrium. *Obstet Gynecol.* 2010;116(1):168-76.
- [2] Dogan E, Celliloglu M, Sarihan E, Demir A. Anesthesia effect of intrauterine lidocaine plus naproxen in endometrial biopsy. *Obstet Gynaecol.* 2004;103(2):347-51.
- [3] Oehler MK, Rees MC. Menorrhagia: an update. *Acta Obstet Gynecol Scand.* 2003;82(5):405-22.
- [4] Baughan DM. Office endometrial aspiration biopsy. *Fam Pract Res.* 1993;15:45-55.
- [5] Vanden BT, Vandanael A, van SD, Wranz P, Lombard C. Combining vaginal USG and office endometrial sampling in the diagnosis of endometrial disease in post menopausal women. *Obstet Gynaecol.* 1995;85:349-52.
- [6] Chandrashekar N, Jyothi GS, Shetty P. Pipelle endometrial biopsy vs dilatation and curettage to diagnose endometrial diseases in abnormal uterine bleeding. *J South Asian Feder Menopause Soc.* 2017;5(2):123-28.
- [7] Singh P. Abnormal uterine bleeding-evaluation by endometrial aspiration. *J Mid-life Health.* 2018;9(1):32-35.
- [8] Opmeer BC, van Doorn HC, Heintz AP, Burger CW, Bossuyt PM, Mol BW, et al. Improving the existing diagnostic strategy by accounting for characteristics of the women in the diagnostic work up for postmenopausal bleeding. *BJOG.* 2007;114:51-58.
- [9] Van den Bosch T, Van Schoubroeck D, Domali E, Vergote I, Moerman P, Amant F, et al. A thin and regular endometrium on ultrasound is very unlikely in patients with endometrial malignancy. *Ultrasound Obstet Gynecol.* 2007;29(6):674-79.
- [10] Gordon SJ, Westgate J. The incidence and management of failed pipelle sampling in a general outpatient clinic. *Aus NZ J Obstet Gynaecol.* 1999;39(1):115-18.
- [11] Polena V, Mergui JL, Zerat L, Sananes S. The role of pipelle mark II sampling in endometrial disease diagnosis. *Eur J Obstet Gynecol Reprod Biol.* 2007;134:233-37.
- [12] Elsandabese D, Greenwood P. The performance of pipelle endometrial sampling in a dedicated postmenopausal bleeding clinic. *J Obstet Gynecol.* 2005;25(1):32-34.
- [13] Aron T, Bela S, Puscasiu L, Capilna ME, Chira L. Diagnostic accuracy of corrier' pipelle endometrial biopsy in comparison with dilatation and uterine curettage. *Gineco.* 2011;7(24):107-10.

- [14] Chaudry A, Javaid M. Clinical usefulness of pipelle endometrial sampling. Pak Armed Forces Med J. 2005;55:122-25.
- [15] Behnamfar F, Khomehchian T, Mazoochi T, Fahiminejad T. Diagnostic value of endometrial sampling with pipelle suction curettage for identifying endometrial lesions in patients with abnormal uterine bleeding. J Res Med Sci. 2004;3:21-23.
- [16] Clark TJ, Mann CH, Shah N, Khan KS, Song F, Gupta JK, et al. Accuracy of outpatient endometrial biopsy in the diagnosis of endometrial hyperplasia. Acta Obstet Gynecol Scand. 2001;80(9):784-93.
- [17] Dijkhuizen FP, Mol BW, Brölmann HA, Heintz AP. The accuracy of endometrial sampling in the diagnosis of patients with endometrial carcinoma and hyperplasia: a meta analysis. Cancer. 2000;89(8):1765-72.
- [18] Rachamalla L, Bhavani V, Byna P. Histological correlation of pipelle endometrial sampling with dilatation and curettage in abnormal uterine bleeding. Int J Reprod Contracept Obstet Gynecol. 2015;4(5):1324-29.
- [19] Patil P, Venigalla S, Harendra Kumar ML, Raju K. A comparative evaluation of the three different methods of endometrial sampling in the diagnosis of perimenopausal bleeding. J Clin Gynecol Obstet. 2014;3(4):133-37.

PARTICULARS OF CONTRIBUTORS:

1. Associate Professor, Department of Pathology, Shri Sathya Sai Medical College and Research Institute, Nellikuppam, Tamil Nadu, India.
2. Professor, Department of Pathology, DM Wayanad Institute of Medical Sciences, Meppadi, Kerala, India.
3. Associate Professor, Department of Pharmacology, Shri Sathya Sai Medical College and Research Institute, Nellikuppam, Tamil Nadu, India.

NAME, ADDRESS, E-MAIL ID OF THE CORRESPONDING AUTHOR:

Dr. Abilash Sasidharannair Chandrakumari,
Associate Professor, Department of Pathology, Shri Sathya Sai Medical College and Research Institute,
Ammappettai, Nellikuppam-603108, Tamil Nadu, India.
E-mail: abey4aris@gmail.com

Date of Submission: **Feb 06, 2018**Date of Peer Review: **Feb 23, 2018**Date of Acceptance: **Apr 02, 2018**Date of Publishing: **May 01, 2018****FINANCIAL OR OTHER COMPETING INTERESTS:** None.